

# Comparison of acetabular reamings during hip resurfacing versus uncemented total hip arthroplasty

SA Brennan,<sup>1</sup> JA Harty,<sup>1</sup> C Gormley,<sup>2</sup> SK O'Rourke<sup>1</sup>

<sup>1</sup> Department of Orthopaedics, Cappagh Hospital, Finglas, Dublin, Ireland

<sup>2</sup> UCD School of Mathematical Sciences (Statistics), Belfield, Dublin, Ireland

---

## ABSTRACT

**Purpose.** To compare the quantity of bone removed from the acetabulum during resurfacing hip arthroplasty versus uncemented total hip arthroplasty (THA).

**Methods.** 62 consecutive patients with osteoarthritis of the hip were prospectively studied. 24 men and 7 women aged 40 to 86 (mean, 59) years underwent Birmingham hip resurfacing. 13 men and 18 women aged 34 to 88 (mean, 61) years underwent uncemented THA using the trident acetabular cup. Obese elderly women at risk of femoral neck fracture and patients with large subchondral pseudocysts or a history of avascular necrosis of the femoral head were assigned to uncemented THA. Acetabular reamings were collected; marginal osteophytes were not included. The reamings were dehydrated, defatted, and weighed.

**Results.** The mean weight of acetabular reamings was not significantly different between patients undergoing hip resurfacing and uncemented THA ( $p=0.57$ ).

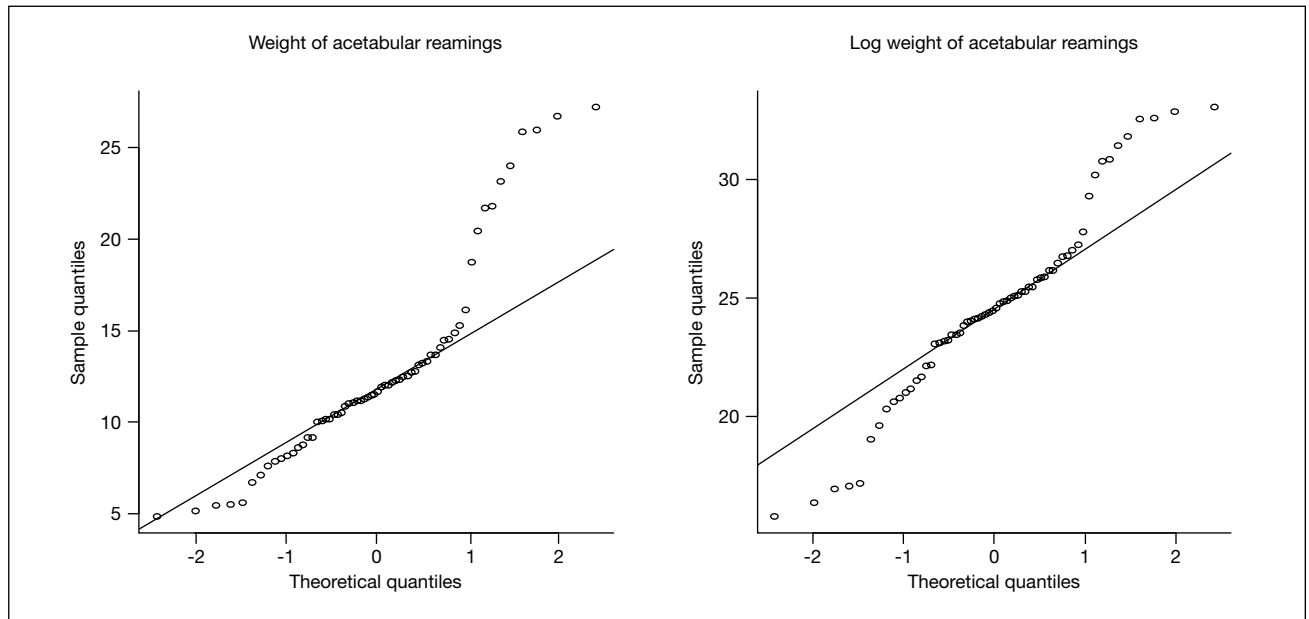
**Conclusion.** In hip resurfacing, the use of an appropriately small femoral component avoids oversizing the acetabular component and removal of excessive bone stock.

**Key words:** acetabulum; arthroplasty, replacement, hip

---

## INTRODUCTION

Metal-on-metal hip resurfacing is increasingly popular in the United Kingdom. <sup>1</sup> It conserves femoral bone stock, has no polyethylene wear debris, and improves stability <sup>2</sup> and range of movement, compared to total hip arthroplasty (THA). <sup>3</sup> Nonetheless, it does not conserve the acetabulum, as the minimum acetabular size is determined by the femoral neck diameter. The acetabular component should be at least 6 mm greater than the minimum femoral head size determined by the neck diameter. In THA, downsizing is feasible because of femoral head excision. The diameter of the acetabulum is the final determinant of the minimum size of the acetabular component in order to achieve an interference fit. To provide a rigid construct and reduce the stress within the acetabular component,



**Figure 1** A Q-Q plot indicates that neither the response (the weight of the acetabular reamings) nor the log of the response (the log of the weights of the acetabular reamings) is normally distributed (illustrated by the deviation from the superimposed solid line).

the external acetabular diameter in a Birmingham hip (Midland Medical Technology, Stoke Prior, UK) is at least 6 mm greater than the external diameter of the prosthetic femoral head. The latter is larger than that for a conventional THA in the same patient and may affect acetabular revision should the hip resurfacing fail. In young and active adults, femoral and acetabular bone removed should be minimised. Hip resurfacing arthroplasty has gained popularity, as its failure mechanism is better understood and the quality of metal-on-metal bearings is improved.<sup>4,5</sup> Whether more bone is removed from the acetabulum during hip resurfacing as compared to uncemented THA remains controversial.<sup>6,7</sup> We therefore compared the quantity of bone removed from the acetabulum in these 2 types of arthroplasties.

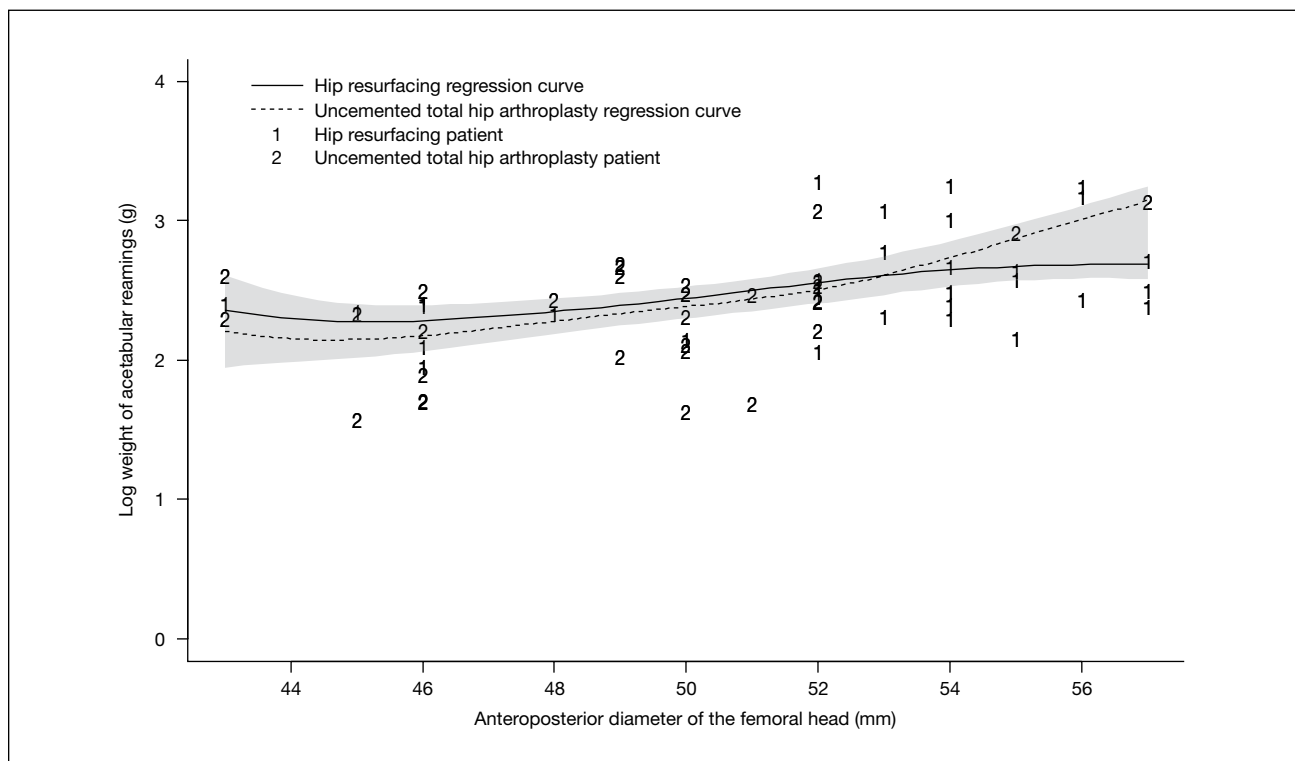
## MATERIALS AND METHODS

Between July and December 2006, 62 consecutive patients with osteoarthritis of the hip were prospectively studied. 24 men and 7 women aged 40 to 86 (mean, 59) years underwent Birmingham hip resurfacing. 13 men and 18 women aged 34 to 88 (mean, 61) years underwent uncemented THA using the trident acetabular cup. Obese elderly women at risk of femoral neck fracture and patients

with large subchondral pseudocysts or a history of avascular necrosis of the femoral head were assigned to uncemented THA.<sup>8</sup>

Patients were placed in a lateral position with padded support; all procedures were via an anterolateral approach. The fascia was divided and the anterior third of the gluteus medius was detached from the greater trochanter, with an osteoperiosteal flap connected to the anterior vastus lateralis. The detached portion of the gluteus medius was moved anterosuperiorly. The gluteus minimus was exposed and elevated with the anterior capsule of the joint; both were split superior to the acetabular margin. The capsule was released from the visible boundaries of the acetabular margin anteriorly and posteriorly. The hip was dislocated by flexion and external rotation and the circumferential capsular division completed.<sup>9</sup>

Acetabular reamings were collected; marginal osteophytes were not included. Using a sterile calliper, the anteroposterior and supero-inferior dimensions of the femoral head were measured following removal of head osteophytes (prior to resection). The larger of the 2 readings was recorded and correlated with the actual size of the femoral component in the resurfacing group. The reamings were dehydrated and defatted by washing with 50 ml of acetone and 50 ml of diethyl ether 5 times, then weighed (using a digital weighing scale calibrated to within 0.001 g) and



**Figure 2** Regression curves for the hip resurfacing and uncemented total hip arthroplasty patients. A reference band for equality is superimposed.

placed in a furnace preheated to 200°C. The remainings were reweighed 2 and 4 hours later to ascertain the consistent dry weight.<sup>10</sup>

The mean weight of acetabular remainings is affected by the type of arthroplasty and also the acetabular size. Analysis of covariance (ANCOVA) was used to compare the mean bone weight removed after adjustment for covariate effects (acetabular size).<sup>11</sup> The anteroposterior diameter of the femoral head was used as a proxy for the acetabular size (correlation was 0.81 in the resurfacing group).

A Q-Q plot indicated that the response (the weight of the acetabular remainings) was not normally distributed; examination of the Q-Q plot for the log of the weights of acetabular remainings also indicated a lack of normality (Fig. 1). Thus, standard ANCOVA was not applicable, requiring recourse to a non-parametric ANCOVA.<sup>12</sup> Let  $y_{ij}$  and  $x_{ij}$  denote the weight of the acetabular remainings and anteroposterior diameter of the femoral head respectively of patient  $j$  under surgery  $i$ . A suitable model is  $y_{ij} = g_i(x_{ij}) + \epsilon_{ij}$  where the  $\epsilon_{ij}$  are independent  $N(0, \sigma^2)$  distributed and  $g_i(x_{ij})$  is assumed to be a smooth regression function. The regression function is a function of the proxy acetabulum covariate, the anteroposterior diameter

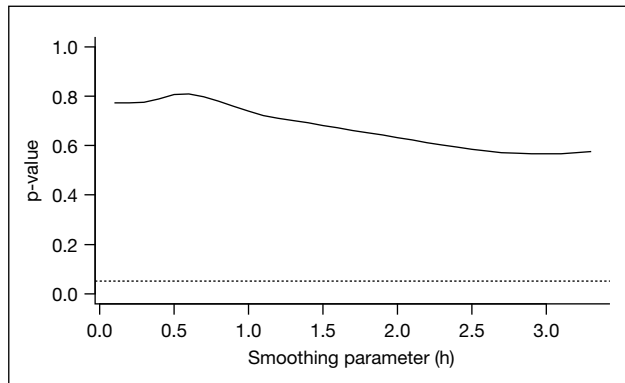
of the femoral head, and is estimated by a non-parametric smoothing technique.

Smooth regression curves were estimated (Fig. 2). A reference band, centred at the mean of the 2 curves and having a width of 2 standard errors, was superimposed on the plot for comparison. The reference band indicated the absence of evidence of a difference in the mean weight of acetabular remainings between the 2 groups. A likelihood ratio test for a difference in the 2 groups resulted in a p value of 0.57 verified this assertion, using the estimated smoothing parameter of  $h=2.88$ .

To avoid the result being dependent on the choice of the scaling parameter, a ‘significance trace’ plotted the p value resulting from the hypothesis test as a function of the smoothing parameter  $h$  (Fig. 3).<sup>13</sup> The curve was consistently above the 5% significance level, suggesting the same conclusion irrespective of the choice of smoothing parameter. The assumption of residual normality was confirmed by the Q-Q plot (Fig. 4).

**RESULTS**

Respectively in the hip resurfacing and uncemented THA



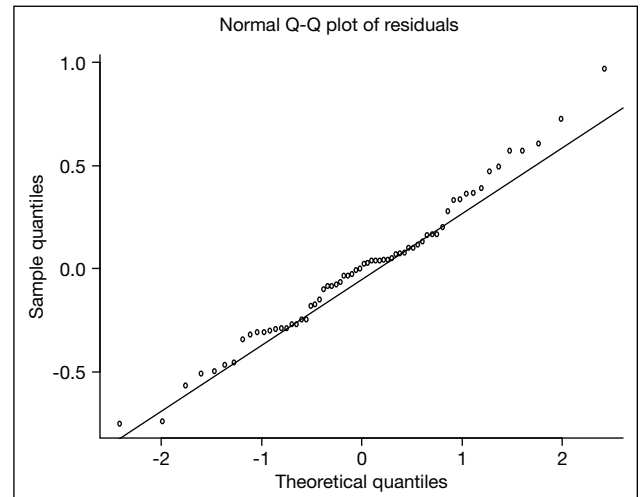
**Figure 3** A 'significance trace' shows the p value as a function of the smoothing parameter. The dashed line indicates the p-value level of 0.05.

groups, the mean external diameters of the acetabulum were 58 mm and 54 mm; the mean diameters of the femoral head after removal of osteophytes were 52 mm and 50 mm; the mean weights of acetabular reamings were 13.787 g and 11.713 g. Using non-parametric ANCOVA to account for the covariate of acetabular size, regression curves displayed no significant difference in the mean weight of acetabular reamings between the 2 groups ( $p=0.57$ , Fig. 2).

## DISCUSSION

In a study comparing the weight of resected bone from the acetabulum between Birmingham hip resurfacing and THA using the press-fit condylar acetabular component (PFC, Depuy, Leeds, UK), 311% more bone was removed with the former treatment (5.6 g vs 1.8 g,  $p<0.001$ )<sup>14</sup> Implant design and surgical technique were significant factors.

The diameter of the acetabular component used (adjusted for patient size by measuring the diameter of the contralateral femoral head) and the quantity of bone removed from the acetabulum were significantly more in hip resurfacing than in uncemented THA; the



**Figure 4** A Q-Q plot verifying the assumption of normally distributed residuals.

difference was more marked in patients with larger femoral-head diameters.<sup>6</sup>

In our study, the weight of acetabular reamings was not significantly different between the 2 groups, which is consistent with a study comparing the size of acetabular component between hip resurfacing and standard THA.<sup>7</sup>

In hip resurfacing, accurate and reproducible preparation of the femoral head and neck enables the use of an appropriately small femoral component without notching the femoral neck, particularly in cases with extensive neck re-modelling and/or osteophyte formation. This minimises the risk of over-sizing the acetabular component and removal of excessive bone stock. However, when hip pathology results in a mismatch between the femoral head and the acetabular component, the acetabular component should be upsized. The femoral head and neck osteophytes should be removed. If not, the enlarged femoral head/neck junction will result in the use of larger femoral components and consequently larger acetabular components.<sup>15</sup>

## REFERENCES

1. National Institute Clinical Excellence. Guidance on the use of metal on metal hip resurfacing arthroplasty. National Institute for Clinical Excellence. London, 2002.
2. Amstutz HC, Thomas BJ, Jinnah R, Kim W, Grogan T, Yale C. Treatment of primary osteoarthritis of the hip. A comparison of total joint and surface replacement arthroplasty. *J Bone Joint Surg Am* 1984;66:228-41.
3. McMinn D, Treacy R, Lin K, Pynsent P. Metal on metal surface replacement of the hip. Experience of the McMinn prosthesis. *Clin Orthop Relat Res* 1996;329(Suppl):S89-98.

4. Capello WN, Trancik TM, Misamore G, Eaton R. Analysis of revision surgery of resurfacing hip arthroplasty. *Clin Orthop Relat Res* 1982;170:50–5.
5. Beaulé PE, Dorey FJ, LeDuff M, Gruen T, Amstutz HC. Risk factors affecting outcome of metal-on-metal surface arthroplasty of the hip. *Clin Orthop Relat Res* 2004;418:87–93.
6. Loughhead JM, Starks I, Chesney D, Matthews JN, McCaskie AW, Holland JP. Removal of acetabular bone in resurfacing arthroplasty of the hip: a comparison with hybrid total hip arthroplasty. *J Bone Joint Surg Br* 2006;88:31–4.
7. Vendittoli PA, Lavigne M, Girard J, Roy AG. A randomised study comparing resection of acetabular bone at resurfacing and total hip replacement. *J Bone Joint Surg Br* 2006;88:997–1002.
8. Shimmin AJ, Back D. Femoral neck fractures following Birmingham hip resurfacing: a national review of 50 cases. *J Bone Joint Surg Br* 2005;87:463–4.
9. Steffen R, O'Rourke K, Gill HS, Murray DW. The anterolateral approach leads to less disruption of the femoral head-neck blood supply than the posterior approach during hip resurfacing. *J Bone Joint Surg Br* 2007;89:1293–8.
10. Gafni RI, McCarthy EF, Hatcher T, Meyers JL, Inoue N, Reddy C, et al. Recovery from osteoporosis through skeletal growth: early bone mass acquisition has little effect on adult bone density. *FASEB J* 2002;16:736–8.
11. Dobson AJ. An introduction to generalized linear models. 2nd ed. CRC; 1945.
12. Young SG, Bowman AW. Non-parametric analysis of covariance. *Biometrics* 1995;51:920–31.
13. Azzalini AW. Nonparametric methods for repeated measurements. In: *Nonparametric functional estimation and related topics*. Vol. 335. Dordrecht, Boston, London: Kluwer Academic Publishers; 1991:337–87.
14. Crawford JR, Wimhurst JA, Villar RN. Bone loss at hip resurfacing: a comparison with total hip arthroplasty. *Hip Int* 2005;15:195–8.
15. Beaulé PE, Antoniadou J. Patient selection and surgical technique for surface arthroplasty of the hip. *Orthop Clin North Am* 2005;36:177–85.