

The application of indirect composite onlays in the restoration of severely broken down posterior teeth

Abstract: Increasing interest has developed among dentists regarding alternatives to traditional full-coverage crowns for the restoration of extensively broken-down teeth that are both aesthetic and less destructive of remaining tooth structure. Indirectly fabricated resin composite onlays may offer a viable and cost-effective treatment option in such cases. This paper describes the clinical rationale for resin-based onlays, and includes a case report illustrating the author's experience with the technique to date.

Journal of the Irish Dental Association 2015; 61 (6): 309-312

Introduction

Posterior teeth that have lost a substantial amount of coronal tooth structure as a result of caries, cavity preparation, fracture, tooth wear, endodontic access or any combination of these frequently present the dentist with a dilemma in terms of treatment planning for subsequent restoration.

Traditionally, the lack of sufficient remaining sound coronal tooth structure following the removal of caries and/or existing intracoronal restorations has often mandated elective root canal therapy and/or crown lengthening to provide the necessary retention and resistance form to support a full coverage crown.^{1,2}

However, the preparation of such weakened residual tooth structure is in itself likely to further compromise the tooth in terms of its biomechanical integrity. The preservation of both radicular and coronal tooth structure is one of the most important factors to protect the tooth from a fatigue fracture.³

There is evidence that more complications are encountered with porcelain jacket crowns and metalceramic crowns compared with partial or full veneer gold crowns.⁴

Patients may also not be fully aware of the increased biological and mechanical risks associated with these invasive restorations.

The amount of coronal tooth structure removed as a result of full coverage crown preparation approaches 60-70%; this reduces to 40% in the case of occlusal onlay preparation.⁵

Furthermore, pulpal morbidity is reduced where less extensive tooth preparation for gold veneers and partial coverage restorations can be carried out.^{6,7}

Plaque control and periodontal maintenance are also likely to be facilitated by the placement of supragingival finish lines.⁸

The development and increased application of adhesively bonded restorations in contemporary practice have enabled the criteria for the prosthodontic assessment of severely broken down teeth for indirect fixed restoration to be reassessed.⁹ Minimal requirements in terms of crown height and parallelism, as well as the degree of retention and resistance form available, can be less stringent where predictable adhesion can contribute to the retention of the restoration. This enables the maximum preservation of tooth tissue while restoring tooth contours and protecting vulnerable cusps.⁵

Material selection

Precious and non-precious metal alloys have been used very successfully for many years in the fabrication of indirect partial coverage restorations.¹⁰ These can be adhesively luted to tooth structure if required, using appropriate cements and conditioning regimens. However, they are frequently unacceptable aesthetically to patients, limiting the choice of a tooth-coloured alternative to that of porcelain or composite resin.



Dr Ray McCarthy BDS FDS MSc MRD

Corresponding author

Dr Ray McCarthy, Fitzwilliam House Dental Practice,
6 Fitzwilliam Street Lower, Dublin 2

T: 01-661 4659 E: info@fitzwilliamdental.com

Composite resin

Modern microhybrid resins demonstrate the necessary hardness, strength and wear resistance for successful clinical performance.¹¹

Fabrication of the restoration outside the mouth allows better control of anatomy, contour, proximal contacts and occlusion as the size of the restoration increases.¹²

More complete curing throughout the material improves physical properties such as flexural and compressive strength and fracture toughness, as well as minimising the significant polymerisation shrinkage associated with directly placed resins. Shrinkage will still occur but it will be limited to that of the luting resin. In an 11-year follow-up study, van Dijken concluded that the major benefit of the indirect approach was to lead to an improvement in marginal adaptation due to the minimisation of contraction stresses.^{13,14}

Although greatly improved, the aesthetics and resistance to staining in the oral environment of composite resins are currently inferior to that achievable with ceramics but they do possess a number of relative advantages:

- they are less susceptible to damage or fracture when being tried in the mouth in situations where there may be resistance to seating due to tight proximal contacts or where axial walls in the preparation have not been sufficiently tapered;
- the occlusion can be more easily assessed and adjusted prior to cementation;
- as the fit surface of the restoration is not etched there is no risk of contamination during try-in;
- any necessary occlusal adjustments post insertion can be more easily and effectively polished; and,
- chips or fractures that may subsequently occur can be repaired relatively easily.

Disagreement exists in the literature regarding the relative suitability of composite resin or ceramic for successful application in posterior load-bearing situations.^{15,16}

Debate has revolved around whether a degree of flexibility in the material allowing absorption of applied stresses during tooth flexure¹⁵ is the more advantageous, or whether a higher modulus material that permits more effective transfer of forces into the underlying tooth structure is the more desirable characteristic.

Magne¹⁷ has argued that because of the higher bond strengths of ceramic to tooth substrate, increased compression can be achieved at the interface, which enhances restoration stability under load.

Data supporting either contention is derived from laboratory testing rather than from *in vivo* comparative clinical trials, which limits the drawing of definitive conclusions.

Regardless of the material selected to restore a posterior tooth, there is convincing evidence that routine coverage of weakened cusps can increase the fracture resistance to a value equivalent to that of an unrestored tooth.¹⁵

Case assessment

An indirect restoration may be considered when a substantial three-walled cavity defect greater than one-half to two-thirds of the intercuspal width is present following tooth fracture and the removal of any plastic restorative material (**Figure 1**). The decision to use composite resin to restore such a defect will be informed by key clinical criteria being met in the course of tooth assessment:

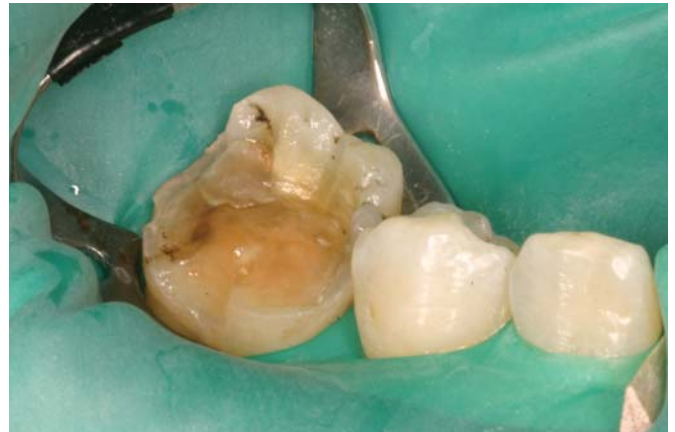

FIGURE 1: An indirect restoration may be considered when a substantial three-walled cavity defect greater than one-half to two-thirds of the intercuspal width is present following tooth fracture and the removal of any plastic restorative material.

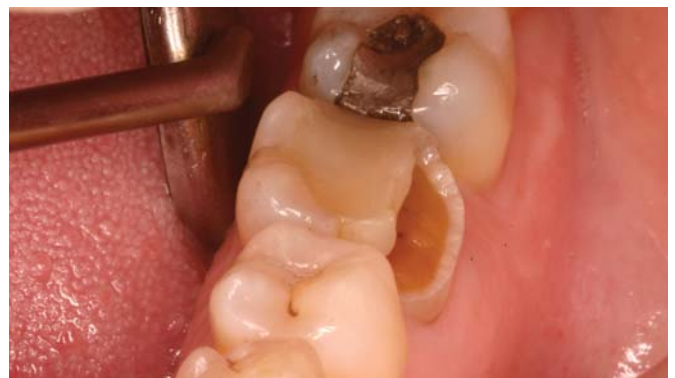

FIGURE 2: Patient presentation.

- ideally, all margins are located in enamel and are supragingival for predictable bonding;
- the patient demonstrates satisfactory oral hygiene and disease control;
- sufficient interocclusal space is present to allow for occlusal thickness of 1.5-2.0mm;
- if the tooth is endodontically treated, a satisfactory coronal seal must be present;
- the tooth can be effectively isolated for cementation, preferably under rubber dam;
- the presence of posterior disclusion in excursive movements; when only axial loading takes place, increased interfacial stresses resultant from lateral and horizontal forces are avoided; and,
- the presence of destructive occlusal habits such as bruxism is a relative contraindication given that compliance with a protective occlusal splint cannot always be assured.

Case report

A 53-year-old female presented with an asymptomatic, non-carious fracture and loss of the buccal wall of 3.6 (**Figure 2**). A large existing mesial-occlusal-distal (MOD) resin restoration was unaffected and the tooth responded positively to vitality testing. The tooth exhibited no thermal sensitivity. Periapical radiography revealed no abnormalities.

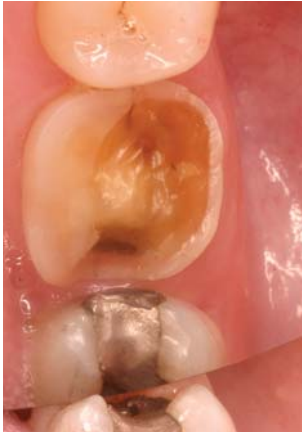

FIGURE 3: Tooth preparation.

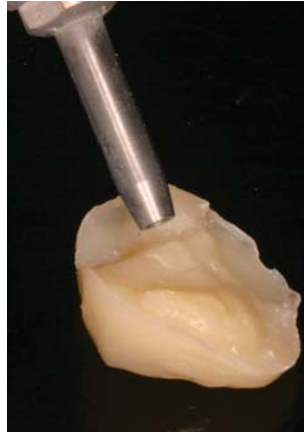


FIGURE 4: Microetcher, Dento-Prep, Ronvig.

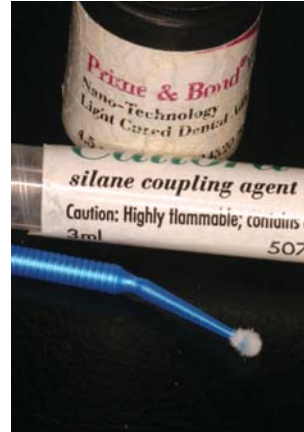

FIGURE 5: Silanating agent.

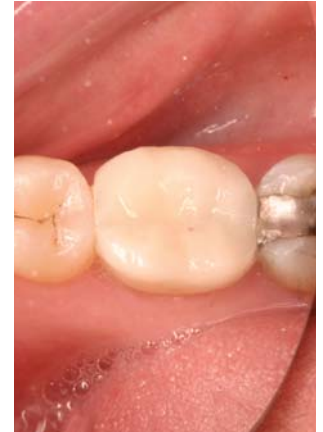

FIGURE 7: Cemented restoration.

After the existing restoration was removed, the remaining lingual cusps were reduced by 1.5mm (2mm over functional cusps) and all cavity margins prepared to a 90° butt joint and finished with Soflex discs. Internal line angles were rounded and smoothed, and care was taken to ensure that the remaining axial tooth walls diverged occlusally without undercut (**Figure 3**).

Remaining coronal tooth structure can be utilised to optimise any features previously present in the cavity outline, such as proximal boxes, which will enhance any mechanical resistance and retention form available.

A full arch impression was made in an elastomeric material (Afinis, Coltene) and the opposing arch recorded in alginate (Xanthalgin, Heraeus).

As the presence of canine guidance in this case provided posterior disclusion, it was not necessary to mount the working casts in a semi-adjustable articulator. Precise interdigitation of the teeth in maximum intercuspation obviated the need for an interocclusal jaw record.

Little or no additional tooth preparation was necessary on the cavity floor, decreasing the likelihood of significant postoperative sensitivity. In the case of teeth heavily restored over a long period, secondary dentine formation is more likely to have resulted in tubular occlusion, and reduced or absent dentinal sensitivity.

Exposed dentine can be protected from bacterial contamination and thermal sensitivity by immediate dentine sealing¹⁸ and/or the placement of an appropriate base material such as glass ionomer or flowable composite resin.

Although the relative simplicity of the laboratory procedures lends itself to a rapid turn-around, the intermaxillary clearance was maintained in this case by spot etching a small index of composite on to a portion of the lingual tooth wall, albeit that provisional coverage is recommended whenever possible.

Provisionalisation in the case of partial coverage restorations is always more challenging and is made more so in these cases by a preparation configuration that is defined by the defect and does not usually possess retention geometry. Following dentine sealing, a thin layer of glycerine gel can be applied to the tooth surface and a provisional soft resin-based material (Fermit, Ivoclar Vivadent) can be placed without cementation.¹⁹

Alternatively, a silicone index for the fabrication of an interim restoration can be made by building up the tooth to contour in the mouth, or on a study cast with wax or old composite resin. A layer of bonding resin can be applied to the preparation, followed by the placement of the matrix filled with

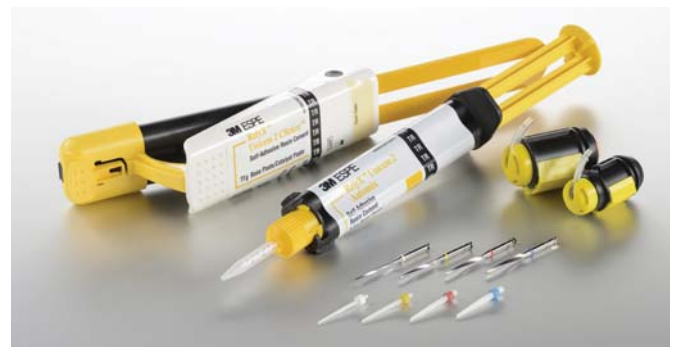

FIGURE 6: Rely X Unicem (3M) is the self-etching, self-curing resin cement used in this case.

autopolymerising resin material and removal of any gross excess. This can subsequently be displaced relatively easily. Good oral hygiene over the short interval until try-in and delivery of the final restoration, should ensure the maintenance of satisfactory gingival health.

In the laboratory, a model was poured in Type IV stone and 0.3mm die spacer applied. Composite resin (Sinfony, 3M) was built up to contour and then cured in a dedicated polymerisation unit (Visio-Vita-Vario, 3M) employing high intensity light and 2.5bar pressure.

Luting

Once the onlay has been tried in, and accuracy of seating and marginal fit verified, the occlusion can be checked and adjusted prior to luting.

Both the fit surfaces of the onlay and tooth substrate were air abraded (**Figure 4**) with 50µm aluminium oxide under rubber dam and subsequently cleaned with alcohol. In the case of margins located in close proximity to the gingiva, placement of retraction cord is advised to ensure moisture control and restriction of the potential for flow of cement into the gingival sulcus.

A silanating agent (**Figure 5**) is applied to the onlay surface in accordance with the manufacturer's instructions (3M Sinfony User Manual). In the case of the self-etching, self-curing resin cement used here (Rely X Unicem, 3M – **Figure 6**), enamel and dentine etching is not deemed necessary in contrast to the recommended three-step protocol for standard dual-curing resin cements.^{20,21}

The restoration was seated with finger pressure initially and was maintained thereafter with a ball burnisher held against the central fossa until preliminary set had taken place. It is a priority at this stage to remove proximal excess with floss while the cement is still in the rubbery phase as it will be difficult or impossible to do so once the material has fully set. The hardened cement can then be removed cleanly with a sharp probe or No.12 scalpel blade from the buccolingual margins and finished with discs, silicone points or wheels, fine diamonds or multifluted carbide burs as required (Figure 7).

Discussion

The majority of the studies in the literature, particularly the older ones, relate to the performance of inlays rather than onlays. These are of short duration (<4 years) and comprise relatively small sample sizes (<100). Several of these studies combine inlays and onlays in their analyses, which confuses their interpretation.^{13,21,22,23} The majority of studies relate to ceramic onlays rather than composite resin onlays and very few directly compare the two.^{15,16,24} Notwithstanding the scarcity of longer term data derived from randomised controlled trials, the information that is available does suggest that the indirect composite onlay technique shows promise as a restorative option for severely damaged teeth.

One study with a recall rate of 94% concluded that, other than for colour match, there were no significant differences between composite and ceramic onlays, which were considered to have performed successfully after evaluation at two years.²⁴ Signore *et al.*²⁵ reported a symptom-free six-year survival rate of 93% for resin composite onlays used to restore cracked posterior teeth. A relatively large sample (n=189) of mainly molar, endodontically treated posterior teeth were observed in a retrospective study over a 24- to 52-month period.²⁶ Tooth survival was found to be 100%, while restoration survival was 97%.

The author's clinical experience with this technique to date consists of a case series comprising 44 onlays in 19 male and 20 female patients, of which 24 were placed in the maxilla and 20 in the mandible. Of the 44 restorations, 31 were placed in molars and 13 in premolars.

The overall mean length of time in service is 17 months, with the oldest restoration at 48 months and the most recent at eight months.

There has been one failure to date, which occurred within three months of insertion. The failure mode occurred at the tooth-cement interface and was attributed to inferior bonding potential of a premolar tooth due to a lack of a continuous peripheral enamel margin.

It is anticipated that detailed clinical assessment using standardised criteria will be carried out in a follow-up study, which will yield more critical clinical information regarding restoration performance and survival.

Conclusion

Composite resin onlays have the potential to offer the benefits of a viable restorative treatment alternative that emphasises the preservation and protection of healthy tooth structure, and is also consistent with contemporary trends in undertaking minimally invasive dentistry wherever possible. An acceptably predictable and aesthetic restoration can be produced more cost-effectively compared to full coverage crowns and indeed ceramic onlay/inlay restorations. This treatment option may be of particular value in circumstances where for financial reasons teeth may be placed at increased risk of fracture in the future by the placement of direct plastic restorations, or possibly extracted because the cost of restoration with traditional full coverage restorations was

deemed prohibitive.

References

1. Schillingburg, H. *Fundamentals of Prosthodontics* (4th ed.). 2012.
2. Satterthwaite, J.D. Indirect restorations on teeth with reduced crown height. *Dent Update* 2006; 33: 210-216.
3. Torbjørner, A. Biomechanical aspects of prosthetic treatment on structurally compromised teeth. *Int J Prosthodont* 2004; 17 (2): 135-141.
4. Cheung, G.S. A preliminary investigation into the longevity and causes of failure of single unit extracoronary restorations. *J Dent* 1991; 19: 160.
5. Edelhoff, D., Sorenson, J. Tooth structure removal associated with various preparation designs of posterior teeth. *Int J Perio Rest Dent* 2002; 22: 241-249.
6. Saunders, W.M., Saunders, E.M. Prevalence of periradicular periodontitis in an adult Scottish subpopulation. *Brit Dent J* 1998; 185 (3): 137.
7. Felton, D., Madison, S. Long-term effects of crown preparation on pulp vitality. *J Dent Res* 1989; 68: 1009.
8. Schatzle, M. The influence of margins of restorations on the periodontal tissues over 26 years. *J Clin Periodontol* 2001; 28 (1): 57.
9. Dietschi, D. A comprehensive and conservative approach for the restoration of abrasion and erosion Part 11. Clinical procedures and case report. *Eur J Esthet Dent* 2011; 6 (2): 142.
10. Yap, A. Cuspal coverage with resin bonded metal onlays. *Dent Update* 1995; 22 (10): 403.
11. Leinfelder, K. Indirect posterior composite resins. *Compendium* 2005; 26 (7): 495.
12. Rocca, G., Krejci, I. Crown and post-free adhesive restorations for endodontically treated posterior teeth: from direct composite to endocrowns. *Eur J Esthetic Dent* 2013; 8 (2): 156-179.
13. Van Dijken, J.W.V. Direct resin composite inlays/onlays: an 11-year follow-up. *J Dent* 2000; 28: 299-306.
14. Belli, R. Mechanical degradation of ceramics versus resin composites for dental restorations. *Dent Mater* 2014; 40 (4): 424.
15. Brunton, P.A. Fracture resistance of teeth restored with onlays of three contemporary tooth-coloured resin-bonded materials. *J Pros Dent* 1999; 82: 167-171.
16. Magne, P. Porcelain versus composite inlays/onlays: effects of mechanical loads on stress distribution, adhesion and crown flexure. *Int J Perio Rest Dent* 2003; 23: 543-555.
17. Magne, P. *In vitro* fatigue resistance of CAD/CAM composite resin and ceramic posterior occlusal veneers. *J Pros Dent* 2010; 104: 149-157.
18. Magne, P. Immediate dentine sealing: a fundamental procedure for indirect bonded restorations. *J Esthet Restor Dent* 2005; 17 (3): 144.
19. Rocca, G.T., Krejci, I. Bonded indirect restorations for posterior teeth: from preparation to provisionalisation. *Quintessence Int* 2007; 38: 371-379.
20. Makkar, S., Mahotra, N. Self-adhesive resin cements: a new perspective in luting technology. *Dent Update* 2013; 40 (9): 758.
21. Rocca, G.T. Bonded indirect restorations for posterior teeth: the luting appointment. *Quintessence Int* 2007; 38: 543-553.
22. Dukic, W. Clinical evaluation of indirect composite restorations at baseline and 36 months after placement. *Operative Dent* 2010; 35 (2): 156-164.
23. Leirskar, J. A four to six year follow-up of indirect composite inlays/onlays. *Acta Odontol Scand* 2003; 61: 247-251.
24. Kaytan, B. Clinical evaluation of composite resin and ceramic onlays over a 24-month period. *Gen Dent* 2005; 53 (5): 329-334.
25. Signore, A. A 4-6 year retrospective clinical study of cracked teeth restored with bonded indirect resin composite onlays. *Int J Prosthodont* 2007; 20: 609-616.
26. Chrepa, V. The survival of indirect composite resin onlays for the restoration of root-filled teeth: a retrospective medium-term study. *Int Endodontic J* 2014; 47 (10): 967-973.

Overcoming the problem of residual microbial contamination in dental suction units left by conventional disinfection using novel single component suction handpieces in combination with automated flood disinfection

Boyle, M.A., O'Donnell, M.J., Russell, R.J., Galvin, N., Swan, J., Coleman, D.C.

Objectives

Decontaminating dental chair unit (DCU) suction systems in a convenient, safe and effective manner is problematic. This study aimed to identify and quantify the extent of the problems using 25 DCUs, to methodically eliminate these problems and develop an efficient approach for reliable, effective, automated disinfection.

Methods

DCU suction system residual contamination by environmental and human-derived bacteria was evaluated by microbiological culture following standard aspiration disinfection with a quaternary ammonium disinfectant or, alternatively, a novel flooding approach to disinfection. Disinfection of multicomponent suction handpieces, assembled and disassembled, was also studied. A prototype manual and a novel automated suction tube cleaning system (STCS) were developed and tested, as were novel single component suction handpieces.

Results

Standard aspiration disinfection consistently failed to decontaminate DCU suction systems effectively. Semi-confluent bacterial growth (101-500 colony forming units [CFU] per culture plate) was recovered from up to 60% of suction filter housings, and from up to 19% of high and 37% of low volume suction hoses. Manual and automated flood disinfection of DCU suction systems reduced this dramatically (ranges for filter cage and high and low volume hoses of 0-22, 0-16 and 0-14CFU/plate, respectively) ($P < 0.0001$). Multicomponent suction handpieces could not be adequately disinfected without prior removal and disassembly. Novel single component handpieces allowed their effective disinfection *in situ* using the STCS, which virtually eliminated contamination from the entire suction system.

Conclusion

Flood disinfection of DCU suction systems and single component handpieces radically improves disinfection efficacy and considerably reduces potential cross-infection and cross-contamination risks.

Clinical significance

DCU suction systems become heavily contaminated during use. Conventional disinfection does not adequately control this. Furthermore, multicomponent suction handpieces cannot be adequately disinfected without disassembly, which is costly in time, staff and resources. The automated STCS DCU suction disinfection system used with single component handpieces provides an effective solution.

J Dent 2015; 43 (10): 1268-1279.

Platelet rich fibrin combined with decalcified freeze-dried bone allograft for the treatment of human intrabony periodontal defects: a randomised split mouth clinical trial

Agarwal, A., Gupta, N.D., Jain, A.

Objective

Polypeptide growth factors of platelet rich fibrin (PRF) have the potential to regenerate periodontal tissues. The osteoinductive property of demineralised freeze-dried bone allograft (DFDBA) has been successfully utilised in periodontal regeneration. The aim of the present randomised, split mouth clinical trial was to determine the additive effects of PRF with a DFDBA in the treatment of human intrabony periodontal defects.

Materials and methods

Sixty interproximal intrabony defects in 30 healthy, non-smoker patients diagnosed with chronic periodontitis were randomly assigned to the PRF/DFDBA group or the DFDBA/saline group. Clinical (pocket depth [PD], clinical attachment level [CAL] and gingival recession [REC]) and radiographic (bone fill, defect resolution and alveolar crest resorption) measurements were made at baseline and at a 12-month evaluation.

Will you still be smiling at the end of the year?

Make sure your practice is profitable in 2016

As Ireland's only specialist dental accountants we're here to help you control your practice costs

QUARTERLY ACCOUNTS

PAYROLL SERVICES

TAX CONSULTANCY

COST OF TREATMENT

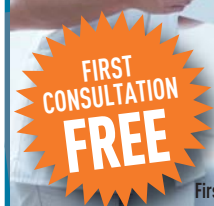MedAccount offer a full range of specialist dental accounting support and advisory services for Associates, Principals, Expense Sharing Partners and Hygienists.

MedAccount Services

96 Lower Georges Street
Dun Laoghaire
Co Dublin

Tel: 01 280 6414

Email: info@medaccount.ie



First consultation FREE OF CHARGE with no obligation to engage