

Radiographic evaluation of the technical quality of undergraduate endodontic 'competence' cases in the Dublin Dental University Hospital: an audit

Précis: An audit examining the technical quality of undergraduate endodontic 'competence' cases in the Dublin Dental University Hospital revealed favourable results compared to benchmark studies, but identified areas for improving quality.

Abstract

Purpose: The aim of this audit was to evaluate the technical quality of undergraduate *de novo* endodontic competence cases in the Dublin Dental University Hospital (DDUH) compared to European standards.^{1,2}

Materials and methods: A radiographic analysis of the number of canals in student 'competence' cases (completed 2009-2010) that met the accepted technical criteria for an ideal root canal treatment was carried out. The benchmark was formulated using accepted European guidelines. Several technical factors were analysed including the apical extent of obturation (within 2mm of radiographic apex), the presence of voids, technical errors and the presence of untreated roots. One hundred and nineteen root canals were initially selected in 78 teeth; however, five teeth were excluded from analysis as the postoperative radiograph was either missing or not diagnostic.

Results: Single-rooted teeth demonstrated voids in 36% of root fillings, and 69% were filled to within 2mm of the apex and there were no detectable technical deficiencies. Multi-rooted teeth demonstrated voids in 38% of root fillings; 60% were filled to within 2mm and 94% of canals demonstrated no deviation from the original canal. Combined results demonstrated that 49% of all the single-rooted teeth and 17% of all the multi-rooted teeth were acceptable within the technical parameters identified in the guidelines.

Conclusions: Analysis of individual technical criteria revealed areas in which the quality was acceptable and others in which it could be improved. Although the overall results appeared poor, they were similar to previous studies of the technical quality of undergraduate root canal treatment.²⁻⁵

Journal of the Irish Dental Association 2012; 58 (3): 162-166.

Introduction

The aim of root canal treatment is to chemo-mechanically clean and obturate the root canal system to prevent or cure apical periodontitis.⁶ Root canal treatment is indicated if the pulp has irreversible disease or is necrotic. It is essential to take appropriate radiographs before, during and after the procedure. Every practitioner is

required to retain a record of the completed treatment in the form of a postoperative radiograph. The technical standard of root canal treatment has been demonstrated to be closely related to success² and a 'proxy' assessment of technical success is the postoperative radiograph of the completed root canal treatment.⁷ Technical guidelines related to preparation and obturation

Mohit Kumar

Great Western Hospitals
NHS Foundation Trust
Great Western Hospital
Marlborough Road
Swindon
United Kingdom

Henry F Duncan

Lecturer and Consultant in Endodontics
Division of Restorative Dentistry
and Periodontology
Dublin Dental University Hospital
Trinity College Dublin
Lincoln Place
Dublin
Ireland

Address for correspondence

Henry F Duncan
Dublin Dental University Hospital
T: 01-612 7356
E: Hal.Duncan@dental.tcd.ie

published by Sjögren (1990)² and the European Society of Endodontology (2006)¹ are accepted as European standards.

It is important to make the distinction between audit and research, audit being designed to examine current practice against recognised 'benchmarks' of best practice. It is not intended to be hypothesis-driven or to generate data as part of an original scientific article. After the initial audit is completed an action plan is generated, implemented and, after a designated time period, re-audited to complete the audit 'loop'. The aim of this audit was to establish the technical quality of root canal treatment performed by undergraduate dental students in the Dublin Dental University Hospital (DDUH).

Materials and methods

The audit was carried out in order to assess the technical quality of undergraduate root canal treatment compared to accepted European guidelines. After a suitable audit area was identified, it was discussed, proposed and approved by the DDUH clinical audit committee.

The target sample for the audit was single- and multi-root 'competence' cases treated by undergraduate students. All third-, fourth- and fifth-year undergraduate students in DDUH complete a 'competence' in both single- and multi-root *de novo* endodontic treatments, which they must pass in order to proceed with their studies. Students are given 'permission to proceed' with the competence by a senior member of staff, after successful completion

of two supervised pre-competence cases in single- and multi-root endodontic treatments, respectively. These competence cases are treated under the supervision of a part-time teacher and are approved afterwards by a senior staff member; however, they are designed to be an assessment of the student's endodontic ability and therefore should be essentially unassisted. During the audit all of the 'competence' forms were retrieved for single- and multi-rooted endodontic treatments completed in DDUH in the year 2009-2010. A total of 46 single- and 32 multi-rooted competence cases were identified for the purpose of this audit. The single roots were analysed per tooth, while multi-rooted canals were initially analysed individually and thereafter combined per tooth. Premolar teeth appear in both single- and multi-root categories, depending on the number of roots that the chosen tooth exhibited. It is established within the DDUH guidelines that although premolar teeth are permissible as part of the multi-root competence, molar teeth should be used if available.

The root canal instrumentation (in the observed period) was generally carried out by traditional hand instrumentation using a step back technique; however, hand and rotary nickel titanium (as a result of a new teaching protocol) was employed in selected later cases. The teeth were obturated with International Organisation for Standardisation (ISO) corresponding gutta-percha points using a lateral condensation technique.

A pro forma sheet (**Appendix 1**) was designed to aid analysis using criteria from the European benchmark standards,^{1,2} and the European Society of Endodontology (2006)¹ consensus paper, supplemented by the seminal endodontic outcome study by Sjögren (1990).² From the standards, the relevant technical indicators were identified and the ideal standard defined. The ideal root canal obturation should terminate within 0-2mm of the radiographic apex, have no evidence of voids, should be present in all the root canals, and should be contained within the original canal anatomy with no evidence of apical deviation, canal 'ledging' or straightening.^{1,2}

Postoperative radiographs taken from each 'competence' case, using the paralleling technique, were analysed by two assessors (non-consultant hospital doctors – NCHDs) and the relevant data collected on the pro forma sheet. If there was disagreement between the NCHDs, a third assessor (Consultant) was asked to adjudicate; there was inter-observer disagreement in five cases. All single-rooted and the majority of multi-root postoperative radiographs were available electronically and were assessed using the measuring software in the Dimaxis system (Dimaxis, Planmeca; Helsinki, Finland). Seven of the multi-rooted cases had old style 'paper' charts, which were obtained to access their respective radiographs. From these charts, radiograph films were assessed using an x-ray viewbox and the distance to the apex measured by a conventional metric ruler.

Results

Single-rooted teeth

One of the 46 cases analysed (2%) had no radiograph available and was eliminated from the audit. In one further case the radiograph was deemed to be undiagnostic and was not included in the analysis. Of

Appendix 1: Pro forma sheet for data collection.

Name:			
Patient no.:			
Tooth no.:			
Root:			
	Yes	No	Undiagnostic radiograph(UR)/no radiograph available
Presence of voids			
Within 0-2mm of radiographic apex			
Over-obturated			
Under-obturated (>2mm short of radiographic apex)			
All roots obturated			
Prepared canal contains the original canal			
No extrusion			
Separated instrument			

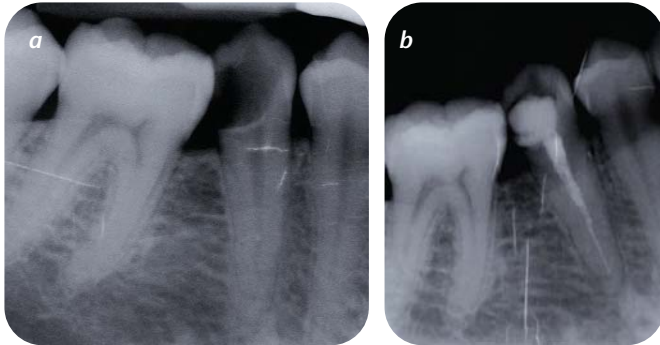
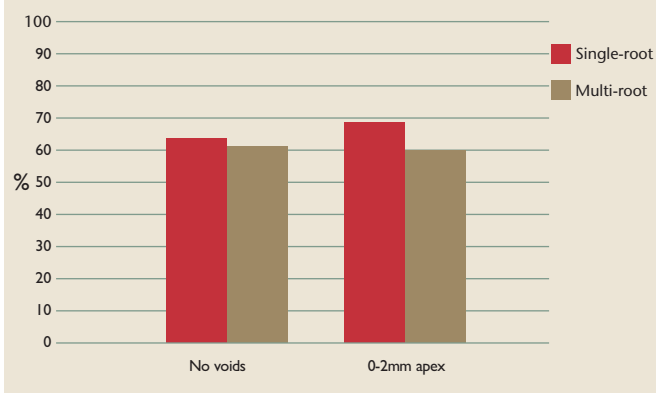


FIGURE 1a: Preoperative periapical radiograph of tooth 45, demonstrating a coronal radiolucency indicative of extensive caries. This premolar had one canal and was considered suitable for the single-root competence test.

FIGURE 1b: Postoperative periapical radiograph of the 45, demonstrating a root canal filling that was under-extended (>2mm from the radiographic apex) and contained voids. The decision was made to re-treat this tooth, before completion of the competence.

TABLE 1: Percentage of canals that did not demonstrate any voids radiographically and are obturated to within 2mm of the apex in single- and multi-rooted teeth.



the remainder, 64% of the root-filled canals had no detectable voids, while 36% of the radiographs demonstrated voids in the canal (Figures 1a and b). In 69% of cases the root filling was within 2mm of the radiographic apex, in 16% it was over-extended and in 15% it was under-extended (Figure 1b) (Table 1). All of the radiographs analysed revealed that the root canal filling material was contained in the original canal. When the investigated factors (voids, length, procedural errors) were combined, 49% of teeth were considered to meet the technical standard for single-root 'competence' cases (Figures 2a and b) (Table 1).

Multi-rooted teeth

A total of 73 canals were assessed from 32 teeth. In one case the radiograph was undiagnostic and in two cases there was no postoperative radiograph available; these were not included in the analysis. A total of 62% of the canals had no detectable voids, while 38% demonstrated voids. In 60% of roots the gutta-percha was

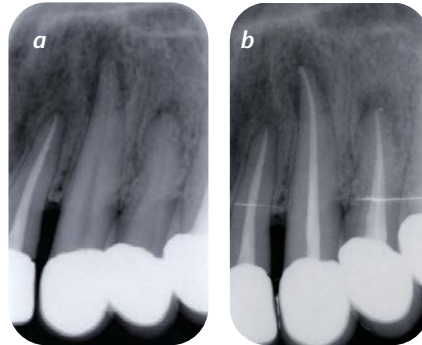


FIGURE 2a: Preoperative periapical radiograph of tooth 23, demonstrating an apical radiolucency indicative of apical periodontitis. This canine was considered suitable for the single-root competence test.

FIGURE 2b: Postoperative periapical radiograph of the 23, demonstrating a root canal filling containing no voids, but evidence of slight overfilling and extrusion of gutta-percha/sealer.

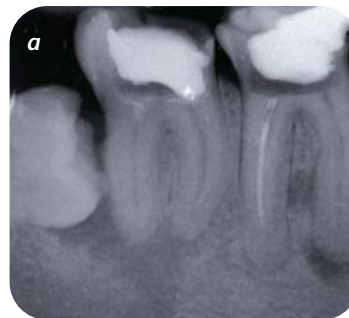

FIGURE 3a: Preoperative periapical radiograph of tooth 47, demonstrating an apical radiolucency indicative of apical periodontitis associated with the 46 and 47. This second molar tooth was considered suitable for the multi-root competence test.

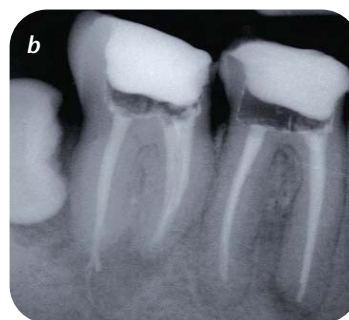
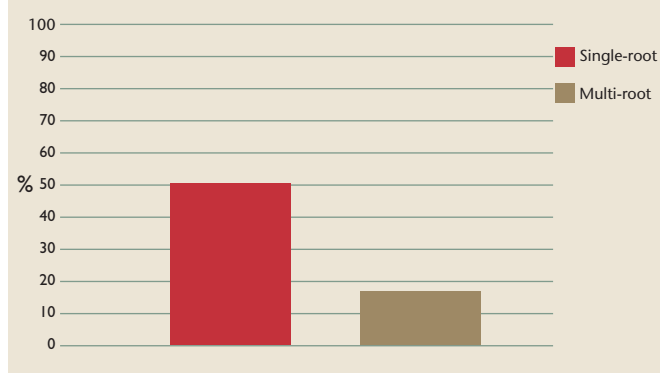


FIGURE 3b: Postoperative periapical radiograph of the 47, demonstrating a root canal filling in the mesial root canals that contained no voids, was obturated to within 0-2mm and was contained within the original canal anatomy. The distal root filling, although not containing any voids, had clear evidence of gutta-percha/sealer extrusion, and was classed as overfilled. This designated tooth 47 as unsatisfactory for the purposes of this technical audit.

within 0-2mm of the radiographic apex, in 9% it was over-extended (Figures 3a and b) and in 31% of the roots it was under-extended (Table 1). A total of 94% of cases demonstrated the prepared canal containing the original canal and 6% of the canals were deviated from the original canal. When the technical factors were combined per canal, 28 of the 73 canals (38%) were considered satisfactory. When the individual canals of multi-rooted teeth were collated, 45% of teeth had no detectable voids. A total of 95% of teeth had all roots obturated on postoperative radiographs; 5% of teeth had one or more roots that had been 'missed'. When technical indicators were combined as multi-rooted teeth, five teeth from 29 teeth (17.5%) were considered satisfactory (Figures 3a and b) (Table 2).

TABLE 2: Percentage of single- and multi-rooted teeth that satisfy all technical parameters.



Finally, when premolars (single- and multi-root) are analysed separately, 10 root canals were treated from eight teeth. A total of 80% had no detectable voids, while 20% demonstrated voids. In 80% of roots the root filling was within 0-2mm of the radiographic apex; in 20% it was short. There were no premolar cases demonstrating deviation of the prepared canal.

Discussion

The aim of this audit was to investigate the technical quality of root canal filling by evaluation of postoperative intra-oral radiographs. Current European guidelines were used as a benchmark for the assessment.¹ This audit was not designed to measure the success of root canal treatment as that would require extensive clinical examination and follow-up. However, technical quality is generally considered to be a 'proxy' marker as there is a positive correlation between high technical quality and endodontic outcome.⁷

Undergraduate 'competence' cases were selected as they reflect by regulation, a student's own work. It is also implicit that the cases were deemed acceptable to pass the competence, as only successful cases were analysed within the audit. Therefore, it is possible that this standard of treatment may not be representative of 'non-competence' cases. Therefore, this audit does not represent accurately the technical standards of all undergraduate root canal treatment in the DDUH.

The quality of root canal treatment was assessed in a classic Swedish university-based study in which the treatment was similarly carried out by undergraduate students under supervision.² The purpose of their study was to determine the factors that affect the long-term success of endodontic treatment. When assessing the apical level of obturating material in 204 cases, 62% were within 0-2mm of the radiographic apex. A total of 11% of all the teeth were under-obtured, and 27% were over-obtured.² The presence or absence of voids was not assessed in the study. The cases that were obturated to within 0-2mm of the radiographic apex were associated with a significantly better outcome than cases that were either under- or over-obtured. The conclusions stressed the importance of good length control and obturation to within 2mm of the apex for long-term success. The results from Sjögren's classic study were similar to

the results for extent of root canal filling obtained in this audit. In this current audit, 67% of the single-rooted teeth and 60% of the roots in multi-rooted teeth were obturated to within 0-2mm of the radiographic apex. Possible reasons for under-obturation include preparation errors or obliteration of the canal preventing instrumentation of the entire canal, while possible reasons for over-obturation include over-instrumentation, poor length control or excessive pressure during obturation.⁷

Other studies examining the technical quality of undergraduate root canal treatment have been published.^{3-5,8-11} Within Ireland, a similar study investigated the technical quality of undergraduate treatment on single-rooted teeth in Cork University School and Hospital;³ the results of that study compare closely with this audit as 70% (69% of the teeth were obturated to within 0-2mm. The overall number of teeth that were considered 'acceptable' was higher in the Cork study,³ principally because of a smaller number of canals containing voids (10%) than in the current study (36%). It is not clear what accounts for this difference; perhaps it is due to stricter evaluation criteria in the current study or reflects a difference in pre-clinical/clinical teaching between the two schools.

An audit of undergraduate root canal treatment within the UK revealed that only 13% of cases were deemed satisfactory in terms of radiographic quality of the root filling and the distance from the radiographic apex.⁴ The authors concluded that the technical quality of undergraduate student root canal treatment was poor.⁴ Although our study compares favourably with the UK audit, the criteria Hayes *et al.* (2001) used for radiographic assessment were slightly different and could account for at least some of the difference.

Studies from other countries reveal a range in the quality of technical root canal fillings performed by undergraduate students.^{5,8-11} A Greek study reported satisfactory root fillings in 71% of anterior teeth and 39% of molar teeth; however, the multi-rooted teeth were judged per canal and not per tooth, which inflates the reported results.⁵ A study from Turkey revealed 33% of teeth to be technically adequate,⁸ a separate Greek study reported 55% of teeth technically adequate,⁹ and a study from Jordan reported 47% of root canal fillings to be satisfactory,¹⁰ while a Saudi Arabian study reported just 23% of cases to be satisfactory.¹¹ Several findings are common to these studies, with the technical quality of undergraduate root canal treatment being generally poor and single-rooted teeth being completed satisfactorily more often than multi-rooted teeth.^{5,9,10} These features are also evident in the current audit.

The European Society of Endodontology (2006)¹ consensus report states that the postoperative radiograph should reveal a root that is completely filled, with no spaces between the filling and the canal wall. For single-rooted and multi-rooted teeth per canal in the current study, 64% and 62% of cases did not contain voids, respectively. When assessing per tooth in multi-rooted cases, there was a marked decrease to 45% of teeth containing no voids. It can be speculated that there is an increased likelihood of obtaining voids in the roots of multi-rooted teeth due to the undergraduate challenge of the lateral condensation obturation technique in posterior teeth.

All single-rooted teeth and 94% of the roots of multi-rooted teeth had their prepared canals contained within the original canals. This deviation of prepared canals from original canals, only in multi-rooted teeth, would be expected because of the presence of curved canals in molar teeth, which are recognised to be more challenging to instrument effectively. When technical factors were combined, 49% of single-rooted teeth and 17% of multi-rooted teeth were considered satisfactory. This appears low but can be rationalised, particularly in multi-rooted teeth where three to four canals are combined into one tooth. As the presence of voids was relatively high in this audit this 'skews' the data, increasing the number of teeth that are technically unacceptable. Interestingly, voids and obturation within 0-2mm results were very similar for single- and multi-rooted teeth. Unfortunately, although the presented results are poor, they compare or are superior to other results in similar studies in the literature.^{3,4,10,11}

A drawback when assessing mandibular molars was visualising all the root canals on the radiograph, as many overlapped, making effective separation impossible. This was a limitation in assessing these canals, so for the purpose of this audit the mesial canals were considered as one canal. Radiographic parallax methods and altered horizontal angulation of the x-ray tube head could assist in separating the mesial canals in these cases, which reveals an important area for future student teaching. It is interesting to highlight the unavailability of two postoperative radiographs, one electronic for single-rooted and one traditional film for multi-rooted teeth. It is possible that the 'wet' film was misplaced, while this is unlikely with the electronic version. It is hoped that the introduction of the phosphor plate system will reduce the incidence of 'missing' radiographs in the DDUH.

Finally, anecdotally the most frequent tooth chosen for 'competence' for single-rooted teeth was the upper central incisor, which perhaps implies that trauma is a major source of patients for 'competences' within a teaching hospital. A wide range of multi-rooted teeth were used as 'competence', with lower first molars being the most commonly treated teeth.

Conclusions and action plan

This audit demonstrates favourable results for termination of root canal filling when compared to the benchmark standard. The desired aim to achieve obturation to within 2mm of the radiographic apex can be achieved by careful instrumentation and perhaps improved by the continued introduction of new technologies. A specialist's opinion (if available) should be sought without delay if the canal appears to be obliterated during instrumentation to avoid blockage and potential under-obturation. However, in terms of other technical markers, there is a need to highlight deficiencies that can be improved, as the overall result for technically acceptable root canal treatment was poor. A total of 63% of single-rooted cases and 60% of multi-rooted cases were considered acceptable in terms of no voids; this was considered too low. There is a need to improve obturation techniques to have the root "completely filled with no spaces between the filling and the canal wall".¹ As a result of the findings, the following action plan was decided at the DDUH audit committee:

1. Voids can be reduced by the introduction of use of greater tapered gutta-percha points and the need for lateral condensation should be minimised. These gutta-percha points have been introduced to the undergraduate curriculum recently and should reduce the risk of void formation.
2. The use of nickel titanium instruments should be considered in all undergraduate cases for improved length preparation, reduced likelihood of blockage and obturation to within 0-2mm of the radiographic apex. These instruments are thought to improve preparation and prevent the loss of length during preparation.
3. Apex locators should generally be used for accurate working length determination and confirmed with a radiograph. These are to be used routinely within the clinics to improve the length of instrumentation and obturation.
4. Use of an electronic radiograph database in the DDUH should minimise the risk of radiographs that should be retained being misplaced.
5. This audit should be repeated after two years when the integration of the action plan resulting from this audit has come into function.

References

1. **European Society of Endodontology.** Quality guidelines for endodontic treatment: consensus report of the European Society of Endodontology. *Int Endod J* 2006; 39: 921-930.
2. **Sjögren, U., Hagglund, B., Sundqvist, G., Wing, K.** Factors affecting the long-term results of endodontic treatment. *J Endod* 1990; 16: 498-504.
3. **Lynch, C.D., Burke, F.M.** Quality of root canal fillings performed by undergraduate dental students on single-rooted teeth. *Eur J Dent Educ* 2006; 10: 67-72.
4. **Hayes, S.J., Gibson, M., Hammond, M., Bryant, S.T., Dummer, P.M.H.** An audit of root canal treatment performed by undergraduate students. *Int Endod J* 2001; 34: 501-505.
5. **Khabbaz, M.G., Protogerou, E., Douka, E.** Radiographic quality of root fillings performed by undergraduate students. *Int Endod J* 2010; 43: 499-508.
6. **Nair, P.N.** On the causes of persistent apical periodontitis: a review. *Int Endod J* 2006; 39: 249-281.
7. **Whitworth, J.** Methods of filling root canals: principles and practices. *Endod Topics* 2005; 12: 2-34.
8. **Er, O., Sagsen, B., Maden, M., Cinar, S., Kahraman, Y.** Radiographic technical quality of root fillings performed by dental students in Turkey. *Int Endod J* 2006; 39: 867-872.
9. **Eleftheriadis, G.I., Lambrianidis, T.P.** Technical quality of root canal treatment and detection of iatrogenic errors in an undergraduate dental clinic. *Int Endod J* 2005; 38: 725-734.
10. **Barrieshi-Nusair, K.M., Al-Omari, M.A., Al-Hiyasat, A.S.** Radiographic technical quality of root canal treatment performed by dental students at the Dental Teaching Center in Jordan. *J Dent* 2004; 32: 301-307.
11. **Balto, H., Al Khalifah, S., Al Mugairin, S., Al Deeb, M., Al-Madi, E.** Technical quality of root fillings performed by undergraduate students in Saudi Arabia. *Int Endod J* 2010; 43: 292-300.